

10° CONGRESSO NAZIONALE



*Quello che le Linee
Guida Non Dicono*

Napoli
Hotel Excelsior
14-15 aprile 2023

Caso Clinico 8: Triclip, Tricento

Dr.ssa Gabriella Scognamiglio
AORN dei Colli - Ospedale Monaldi
UOC UTIC Cardiologia Vanvitelli

Caso clinico 1

C.S. , anni 78

Fattori di rischio cardiovascolari: Ipertensione arteriosa , DM di tipo 2

Anamnesi patologica remota:

01.2020 : STEMI anterolaterale trattato con PTCA primaria e stenting su IVA, PTCA staged su Cx e MO

Paziente fortemente sintomatico per dispnea

All'ecocardiogramma : severa riduzione della funzione sistolica del ventricolo sinistro, insufficienza mitralica di grado severo da flail del LMP

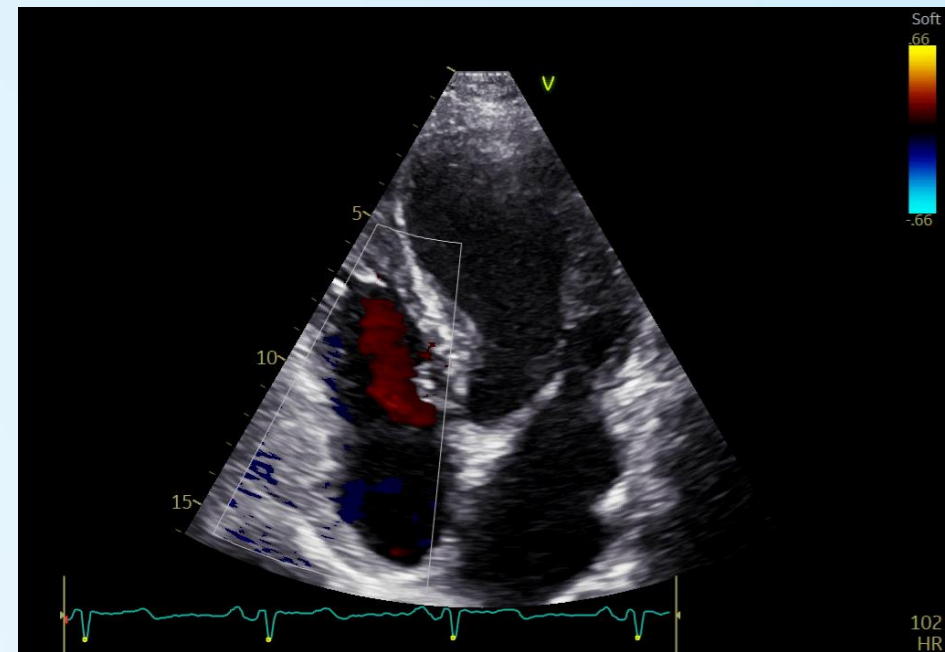
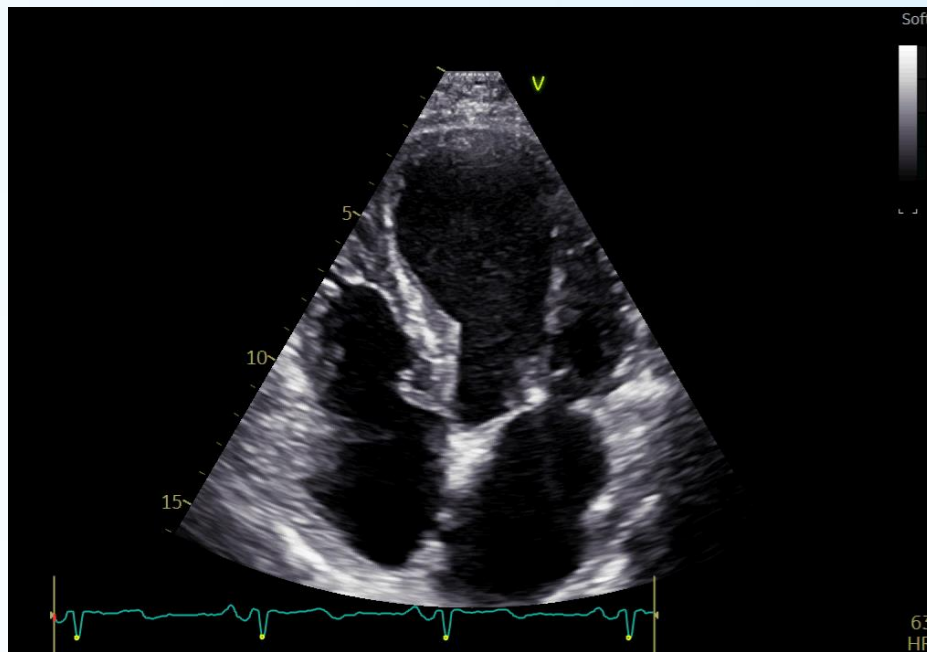
02.2020: Procedura di mitraclip con impianto di 2 clip , insufficienza mitralica residua di grado lieve, assenza di significativo gradiente transmitralico, insufficienza tricuspide moderato-severa

Ottimizzazione terapia medica

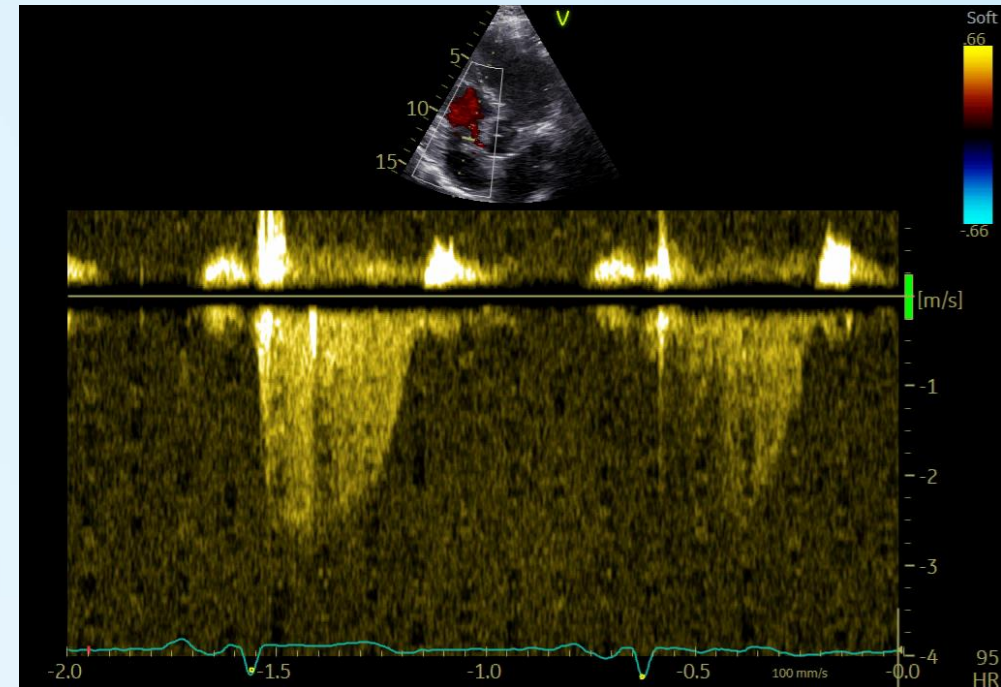
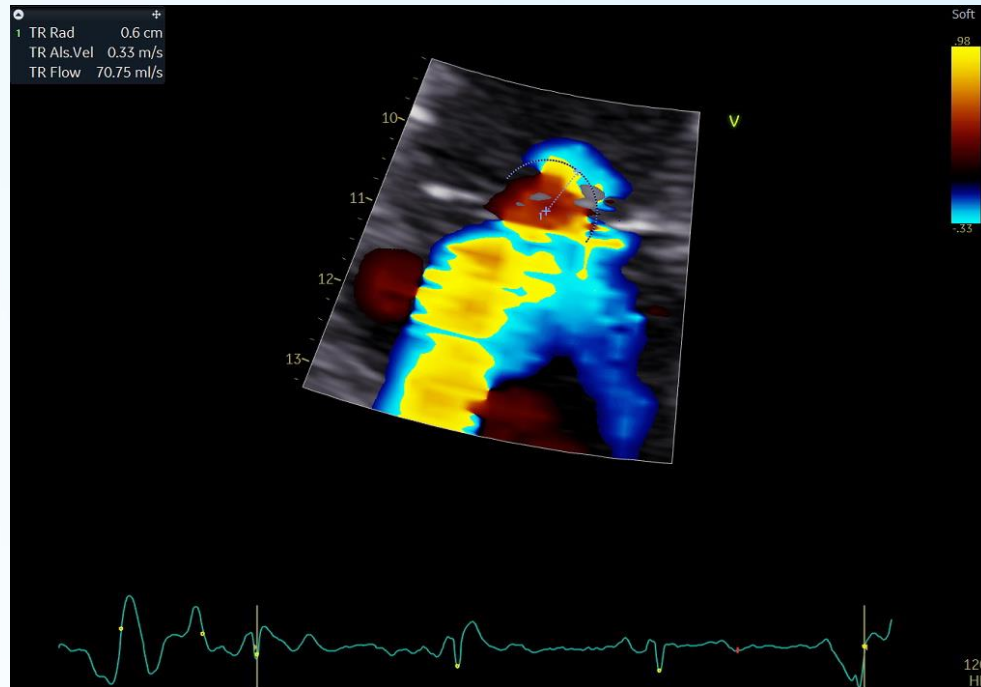
Caso clinico 1

A più di 6 mesi dalla mitraclip e dall'ottimizzazione terapeutica persiste dispnea

Al controllo ecocardiografico insufficienza tricuspидale moderata



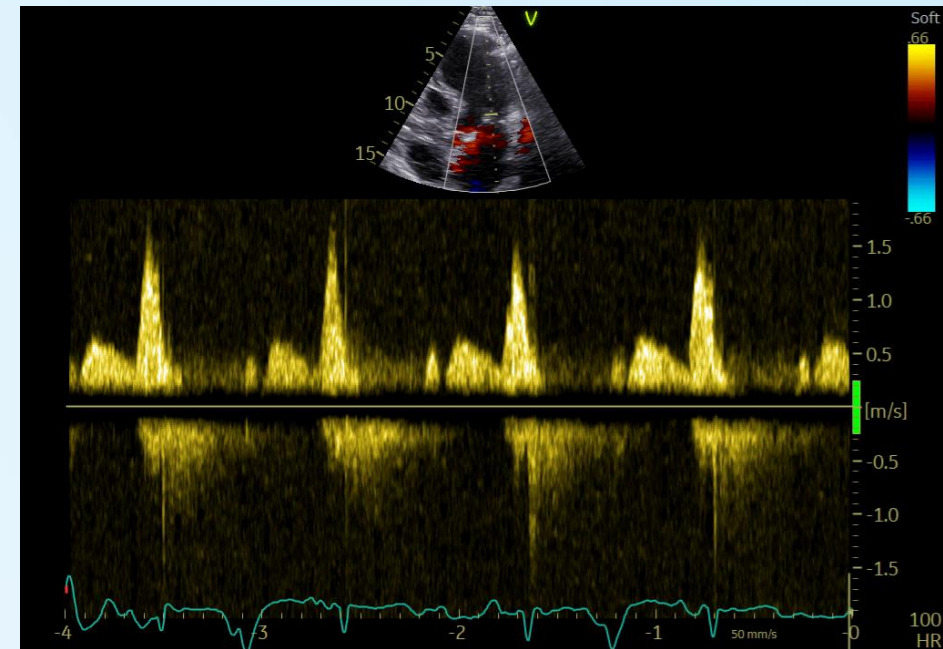
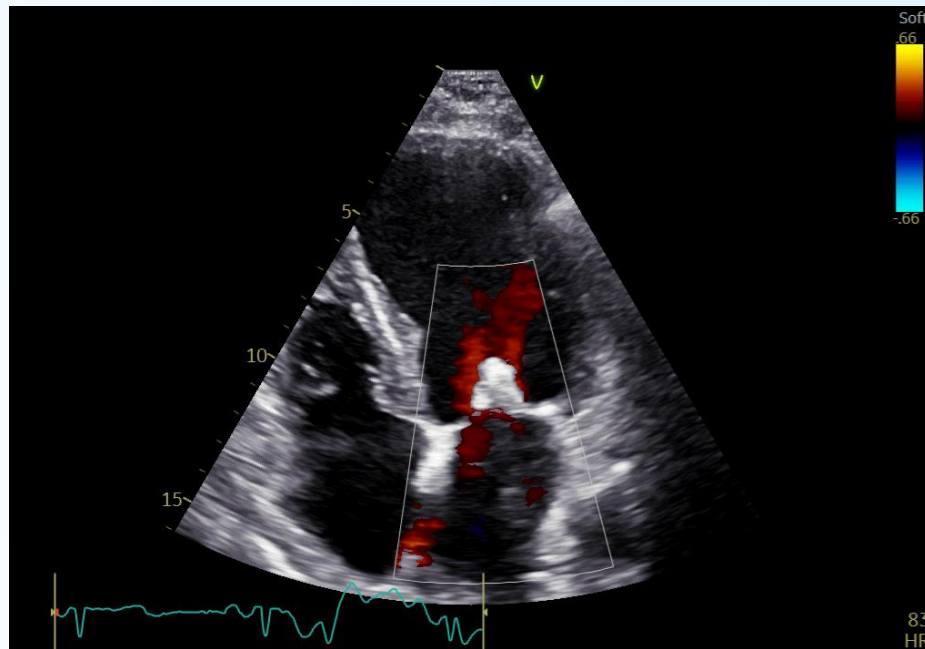
Caso clinico 1



Caso clinico 1

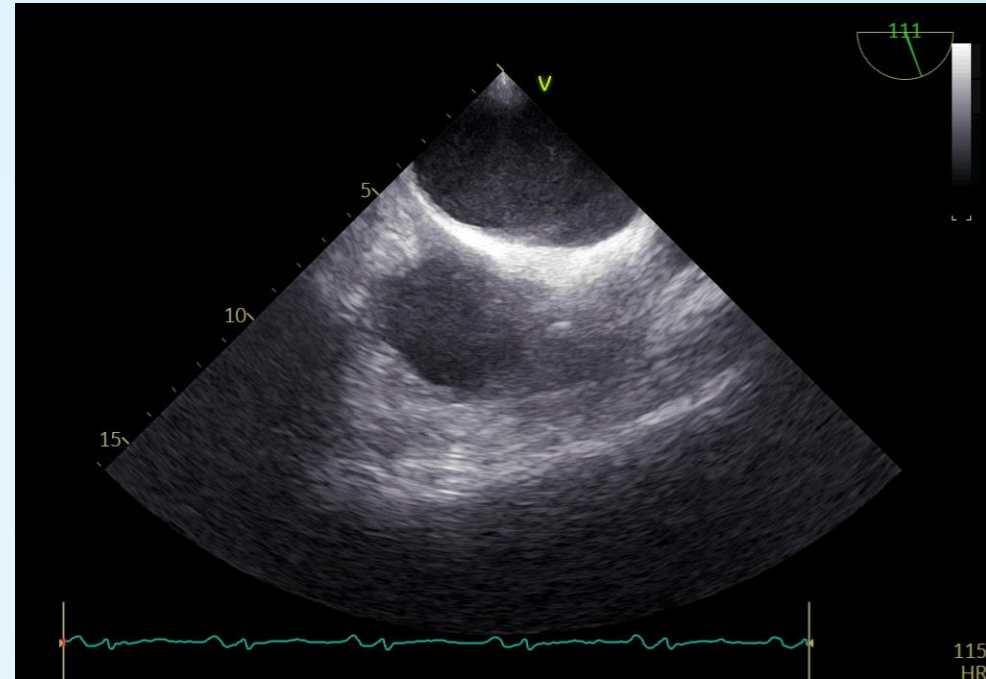
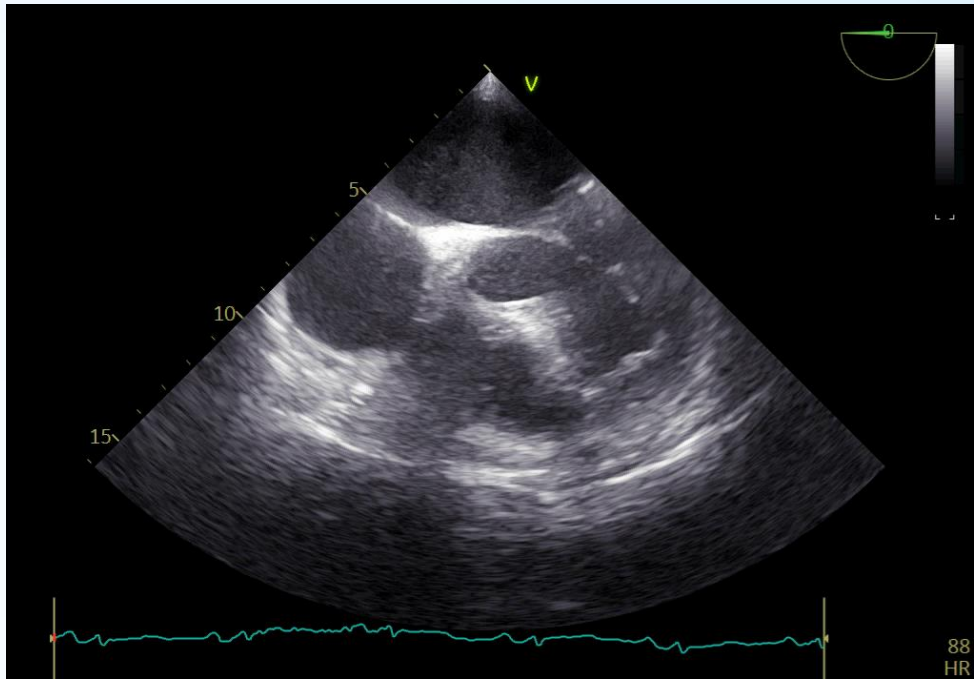
Minima insufficienza mitralica residua

Assenza di gradiente transmitralico



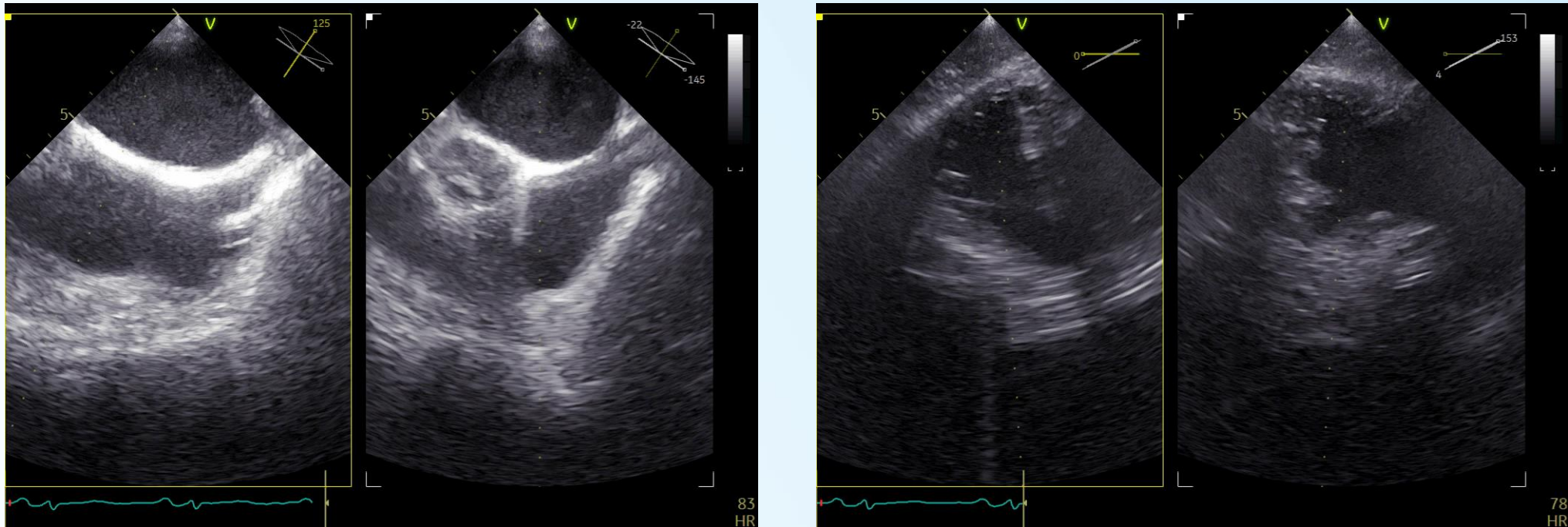
Caso clinico 1

11.2021 Ecocardiogramma transesofageo:

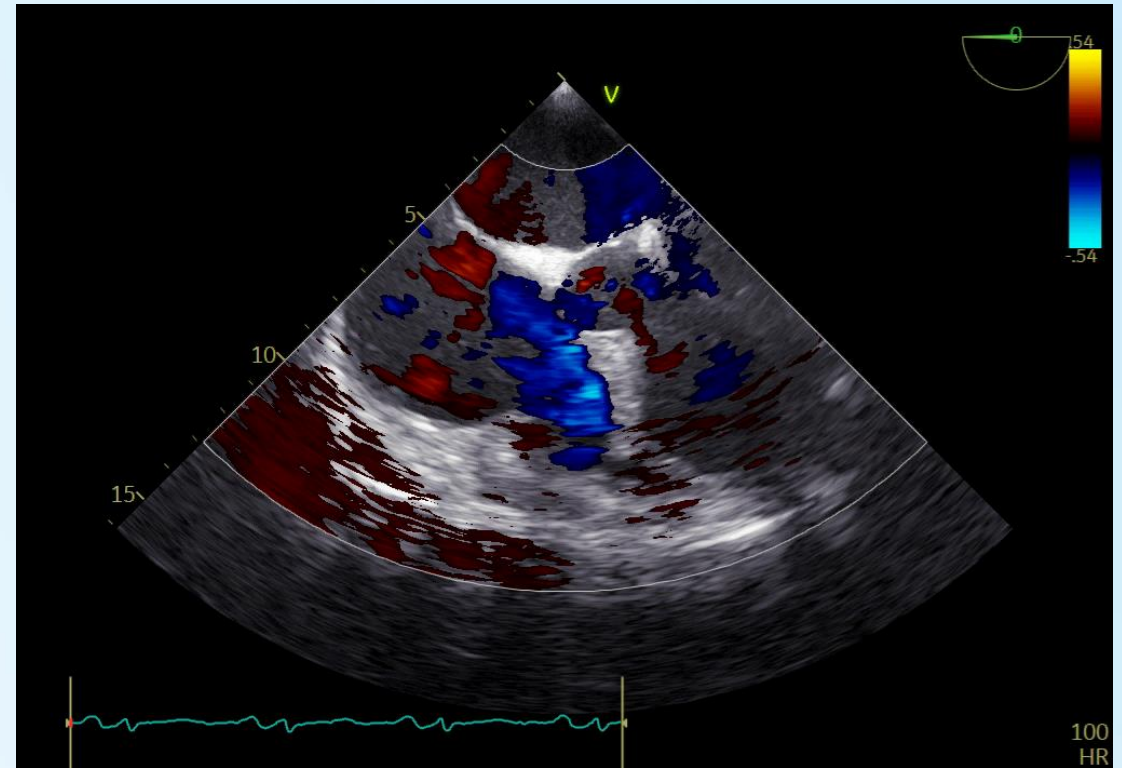
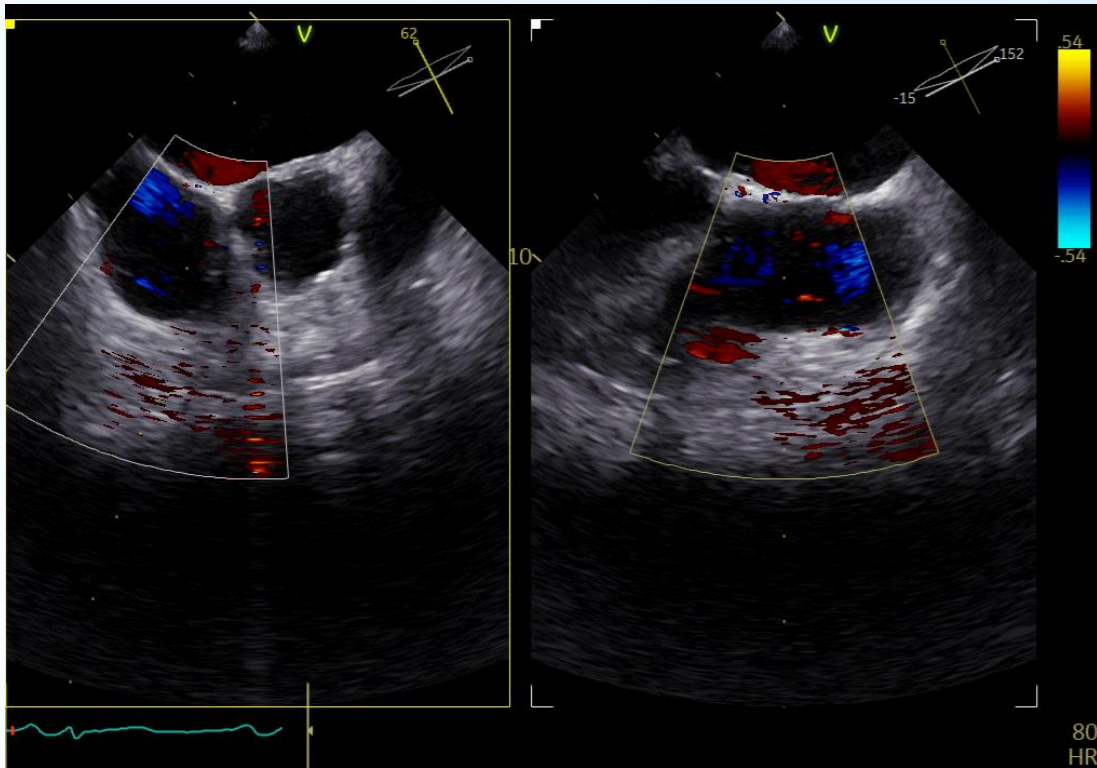


Caso clinico 1

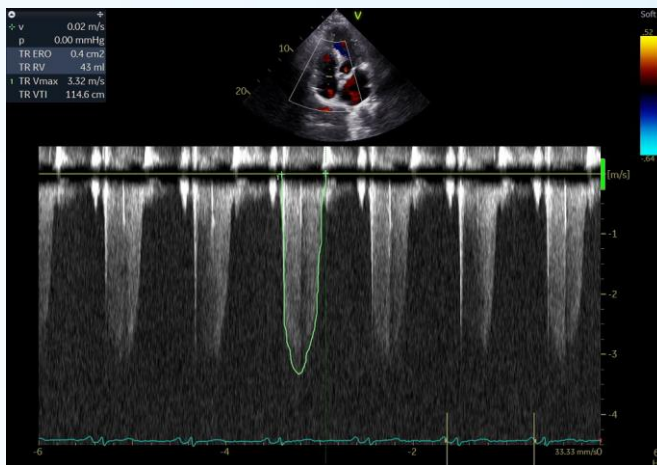
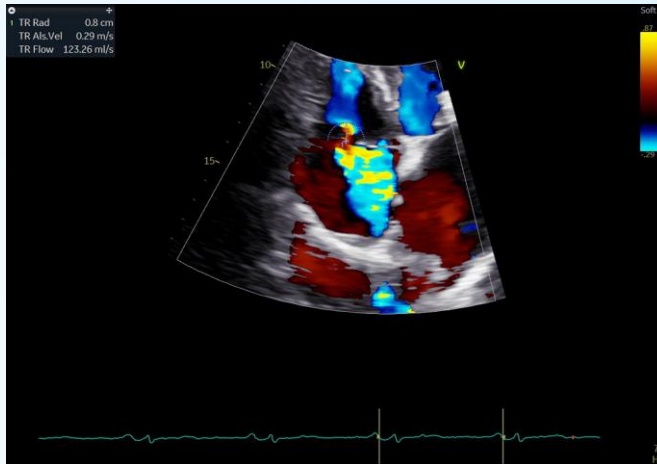
11.2021 Ecocardiogramma transesofageo:



Caso clinico 1



Caso clinico 1



Raggio Pisa =8mm
EROA=40mm²
RV=43ml
Insufficienza tricuspидale di grado severo
Ridondanza dei lembi con prolasso dei lembi anteriore e posteriore

Caso clinico 1

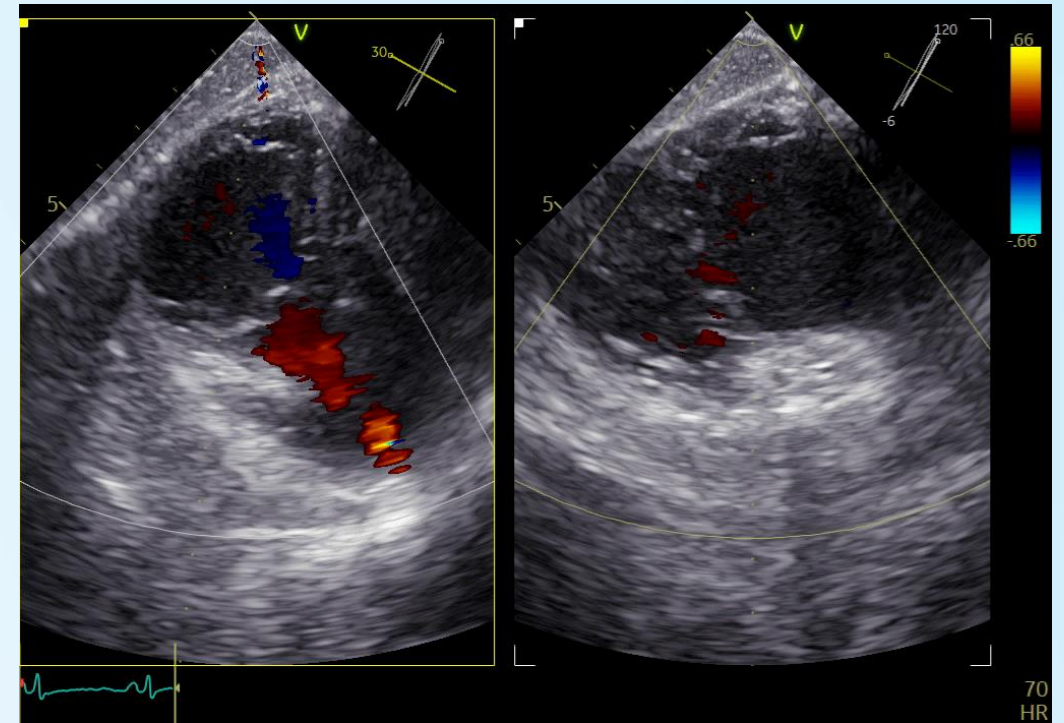
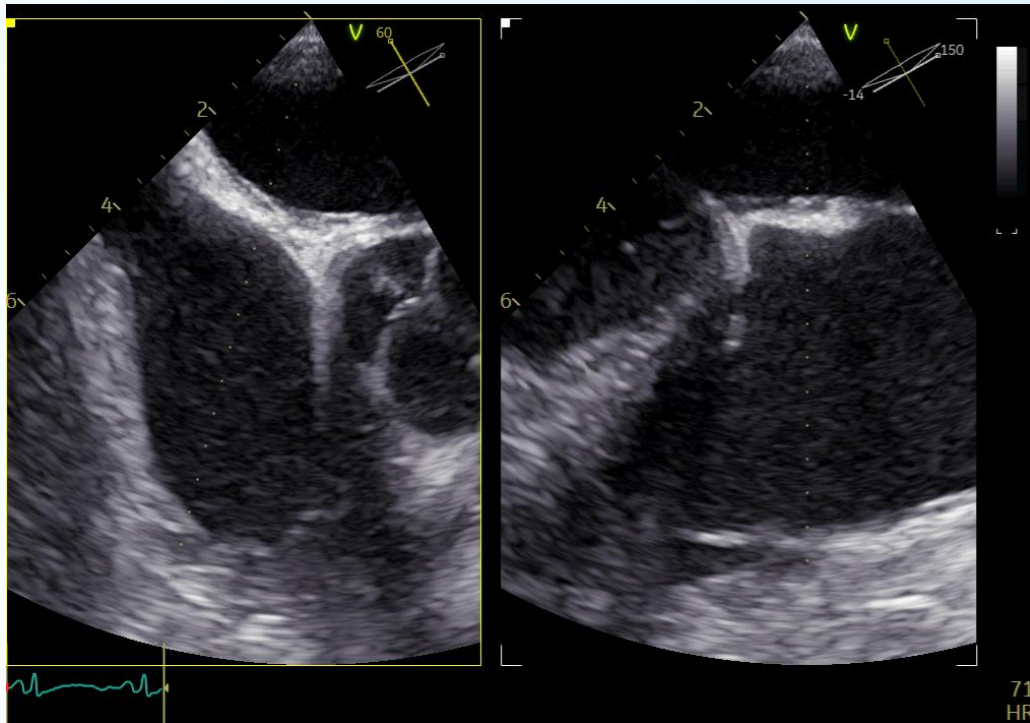
Anatomia favorevole per triclip

Heart team

Si propone Triclip

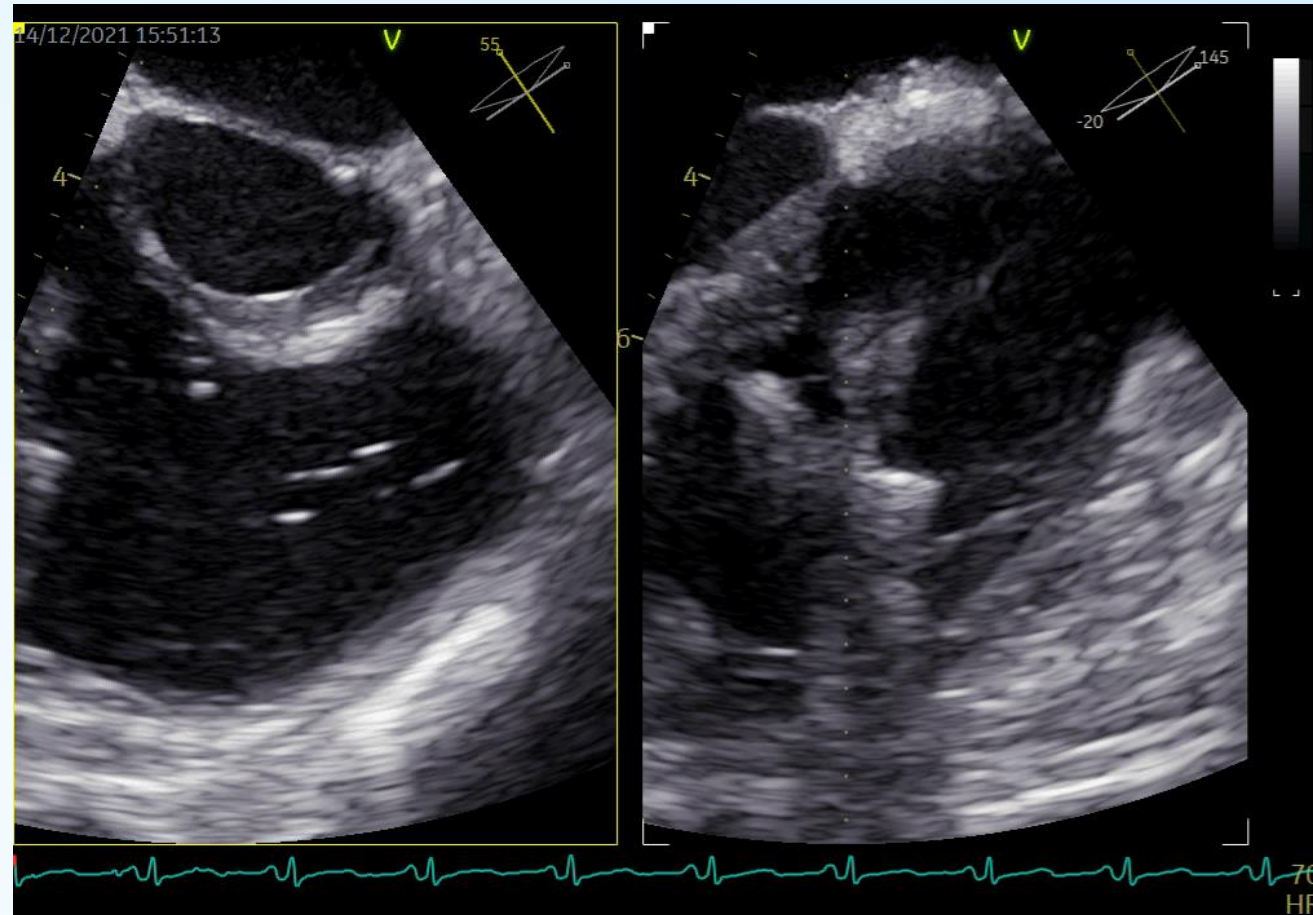
Caso clinico 1

12.2021 procedura di Triclip

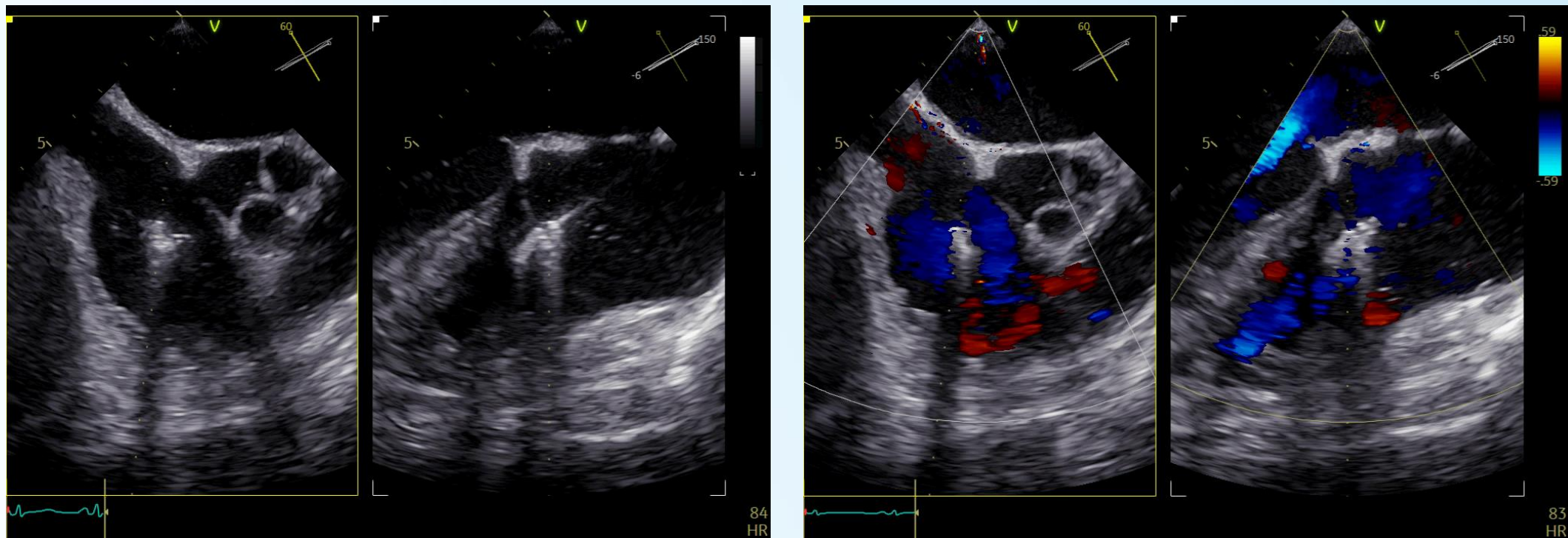


Caso clinico 1

Grasping

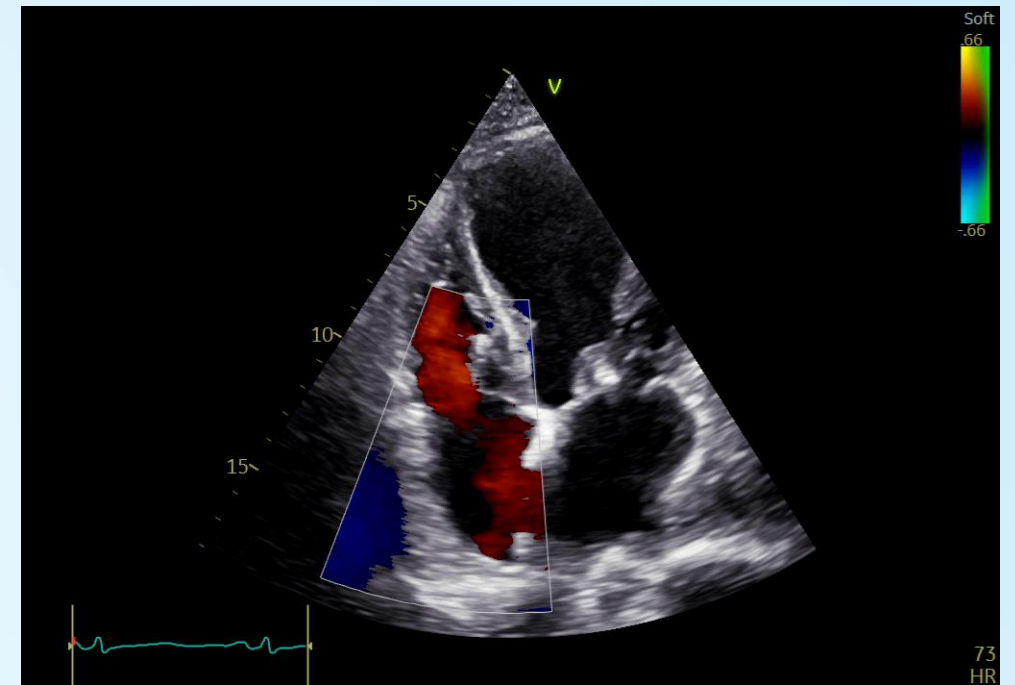
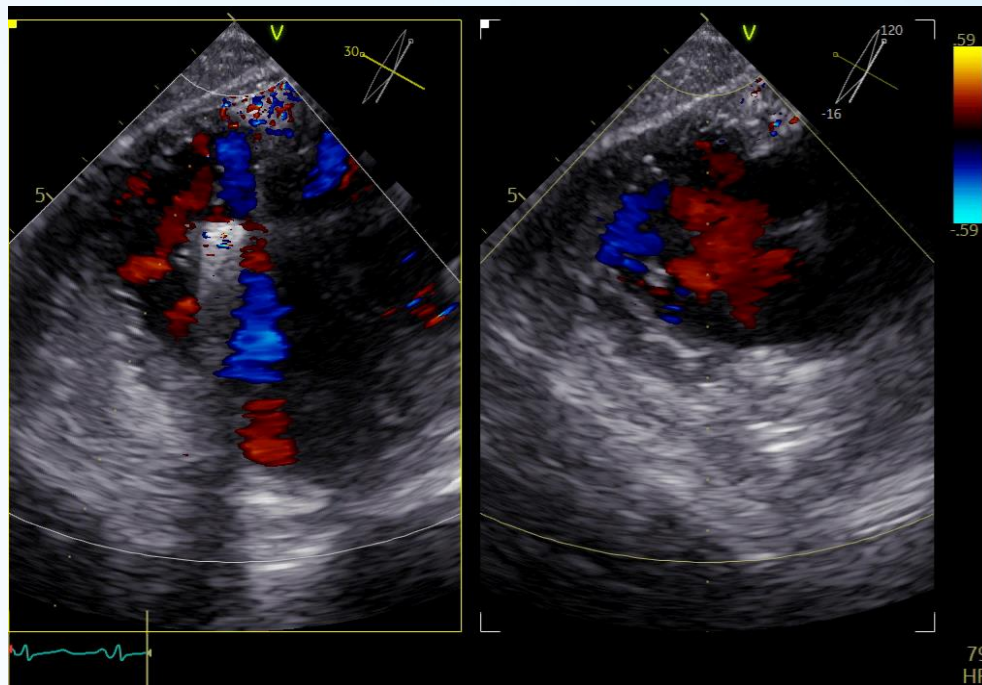


Caso clinico 1



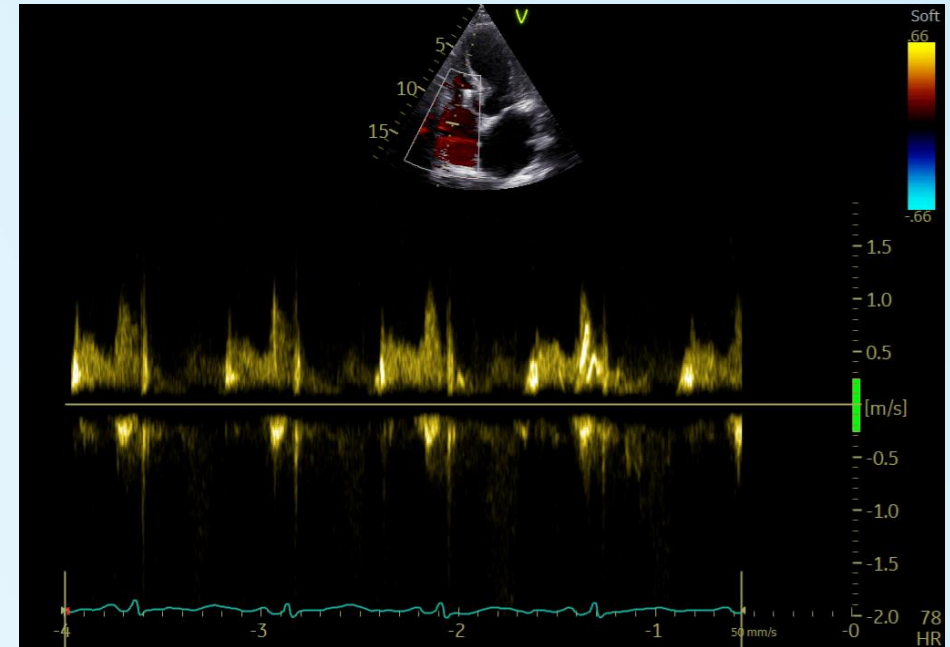
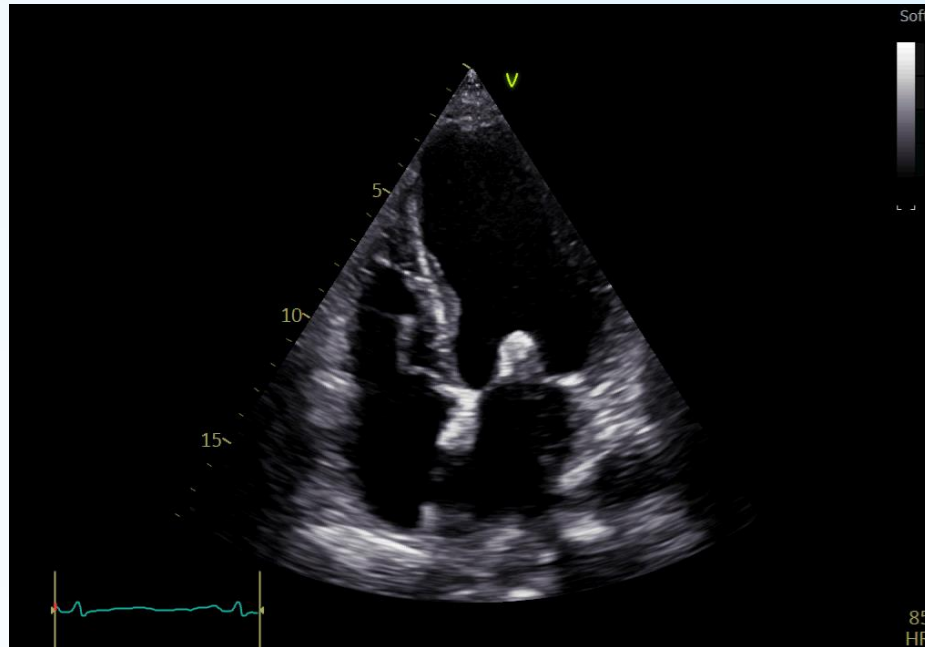
Caso clinico 1

Insufficienza tricuspидale residua di grado lieve



Caso clinico 1

Assenza di gradiente transtricuspidale



Caso clinico 2

D.C. P., anni 77

Fattori di rischio cardiovascolari: ipertensione arteriosa, diabete mellito di tipo 2

Anamnesi patologica:

Nel 2010 dissezione aortica di tipo A sottoposta a impianto di tubo protesico e protesi valvolare Mira 23mm

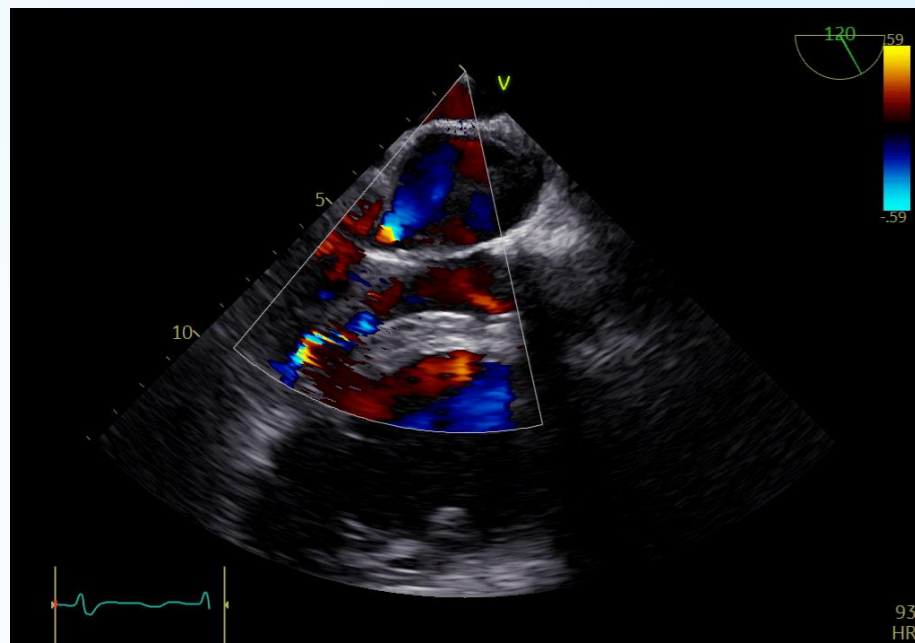
Nel 2019 procedura di mitraclip per insufficienza mitralica moderato-severa (3+-4+/4+) da prolasso bilembo

2020 ricovero per scompenso cardiaco destro ascite, epatopatia da stasi

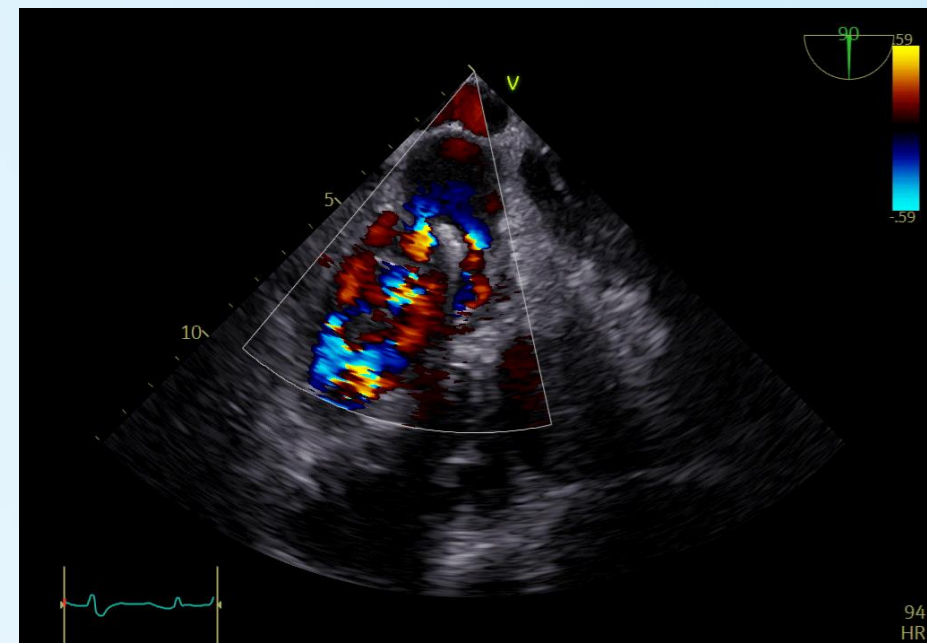
All'ecocardiogramma dilatazione delle sezioni destre, ridotta funzione sistolica del ventricolo destro, insufficienza tricuspide torrenziale

Caso clinico 2

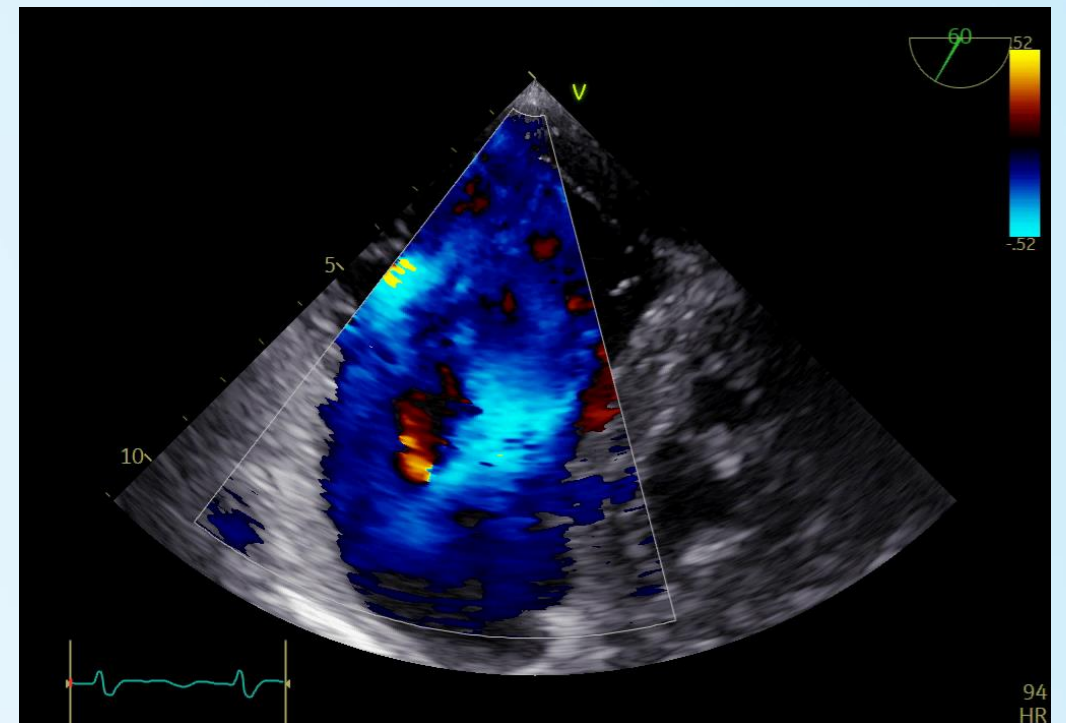
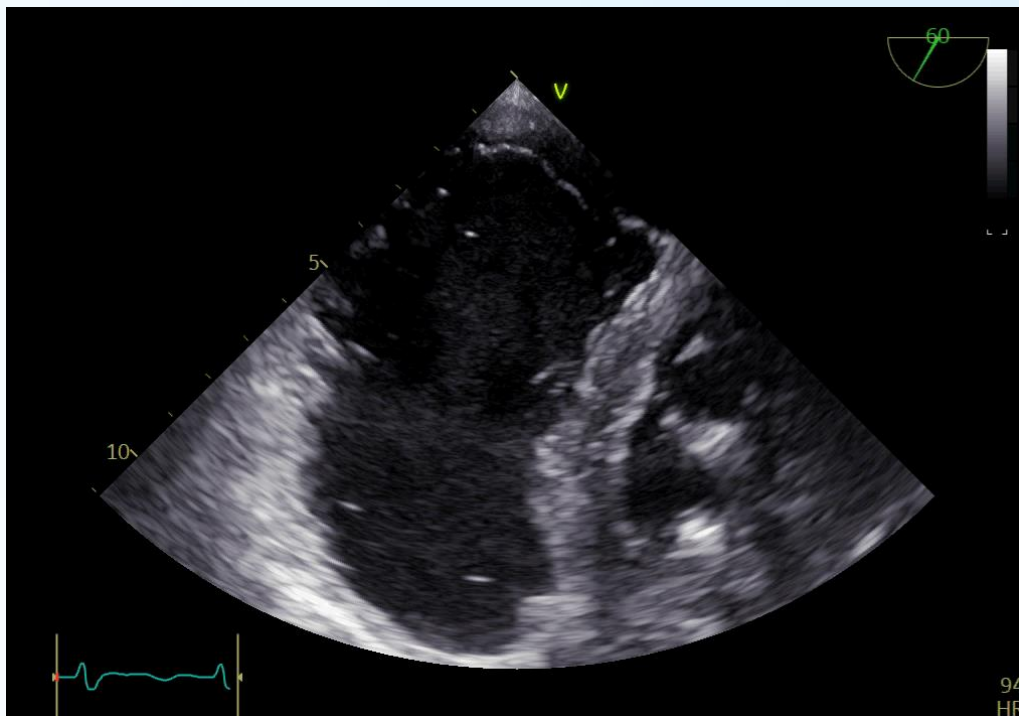
Leak periprotetico aortico di grado lieve



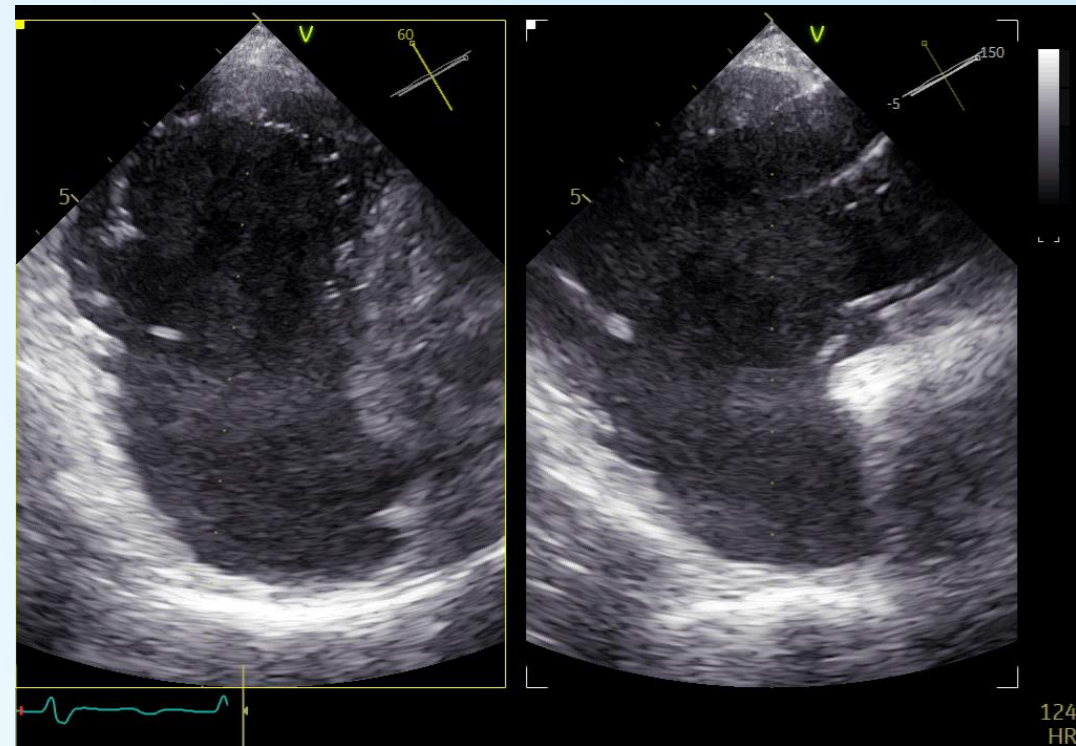
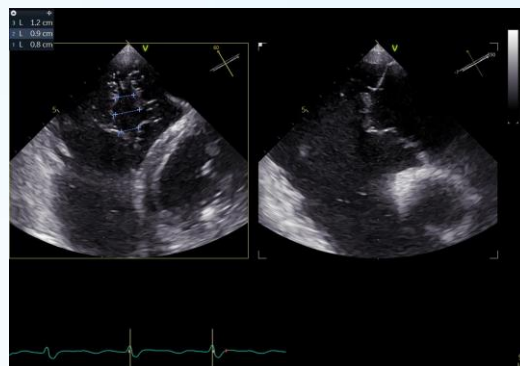
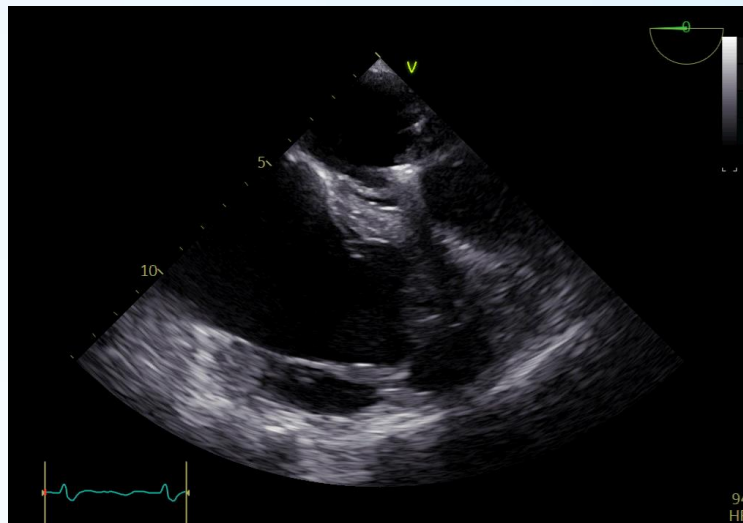
Insufficienza mitralica residua di grado lieve



Caso clinico 2



Caso clinico 2



Caso clinico 2

Ecocardiogramma transesofageo:

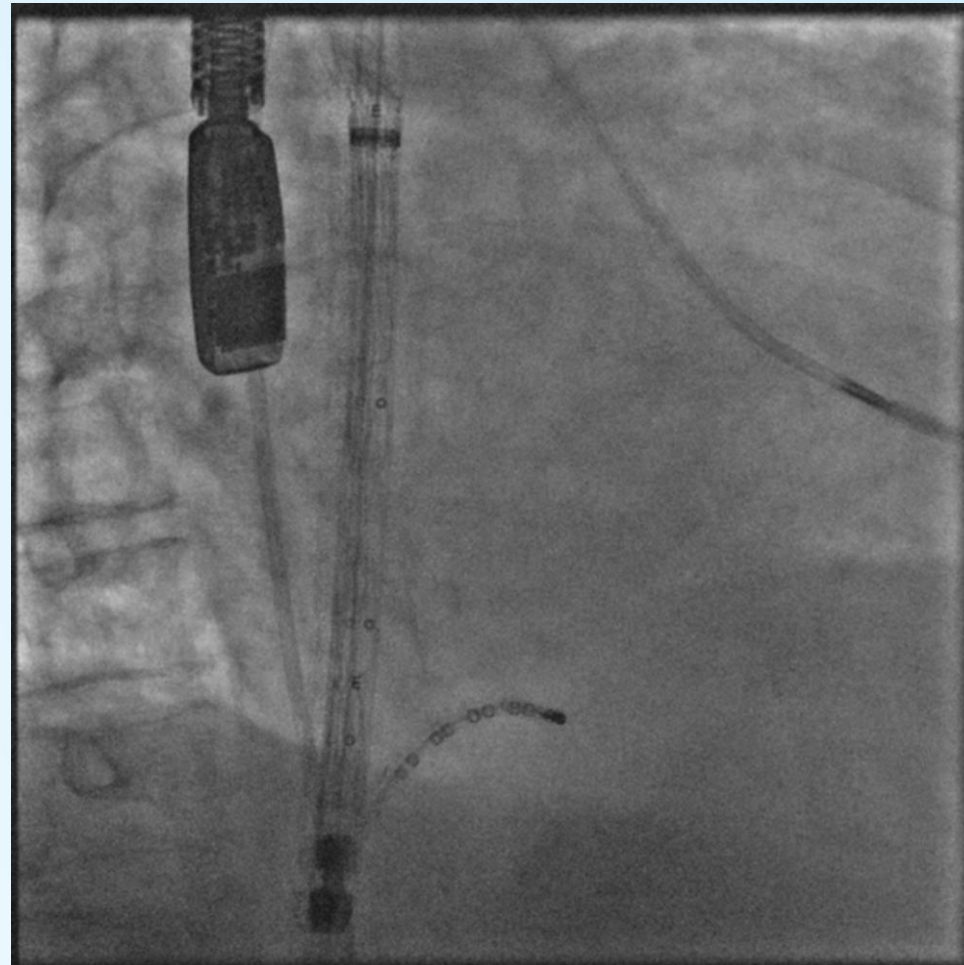
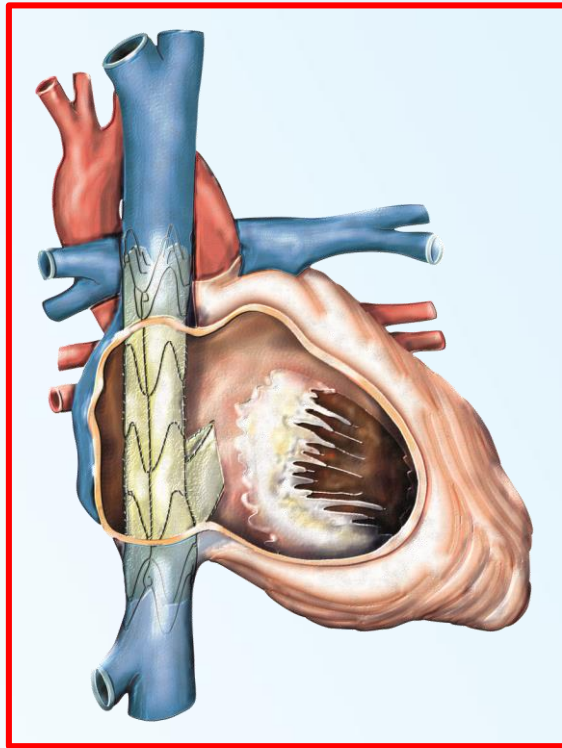
Insufficienza tricuspидale torrenziale da ampio deficit di coaptazione tra i lembi

Dilatazione dell'anello tricuspидalico e delle sezioni destre

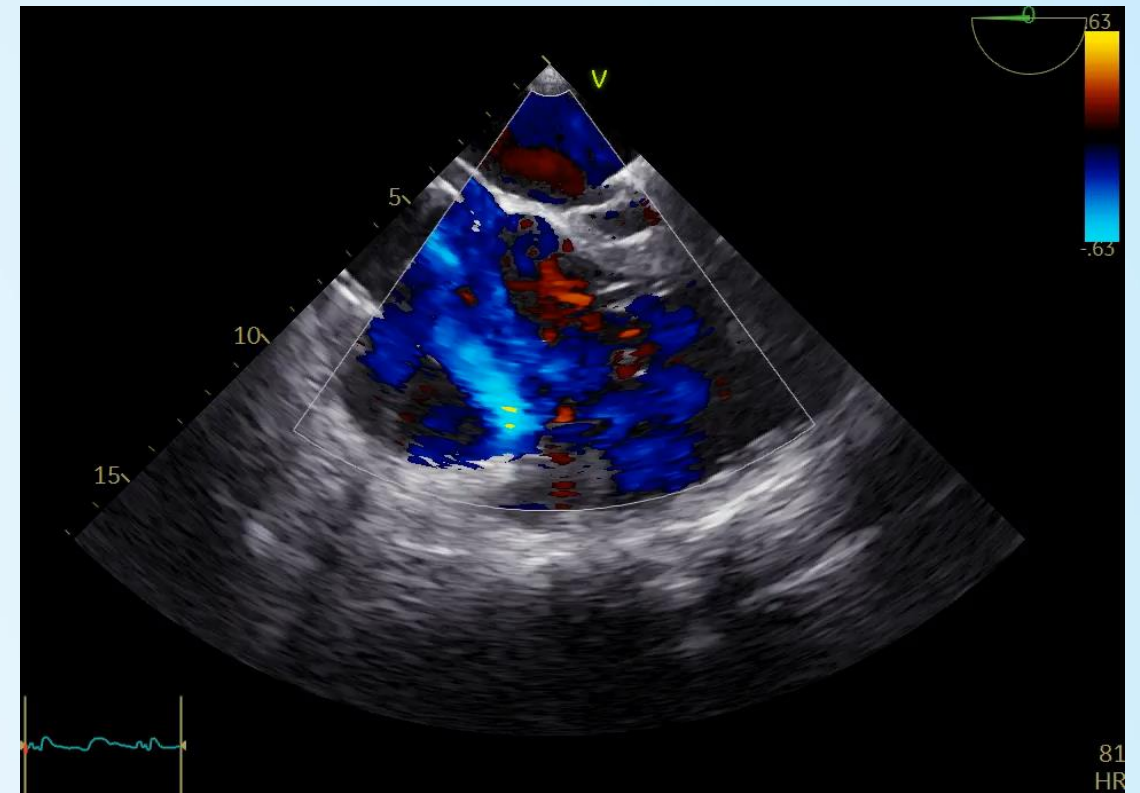
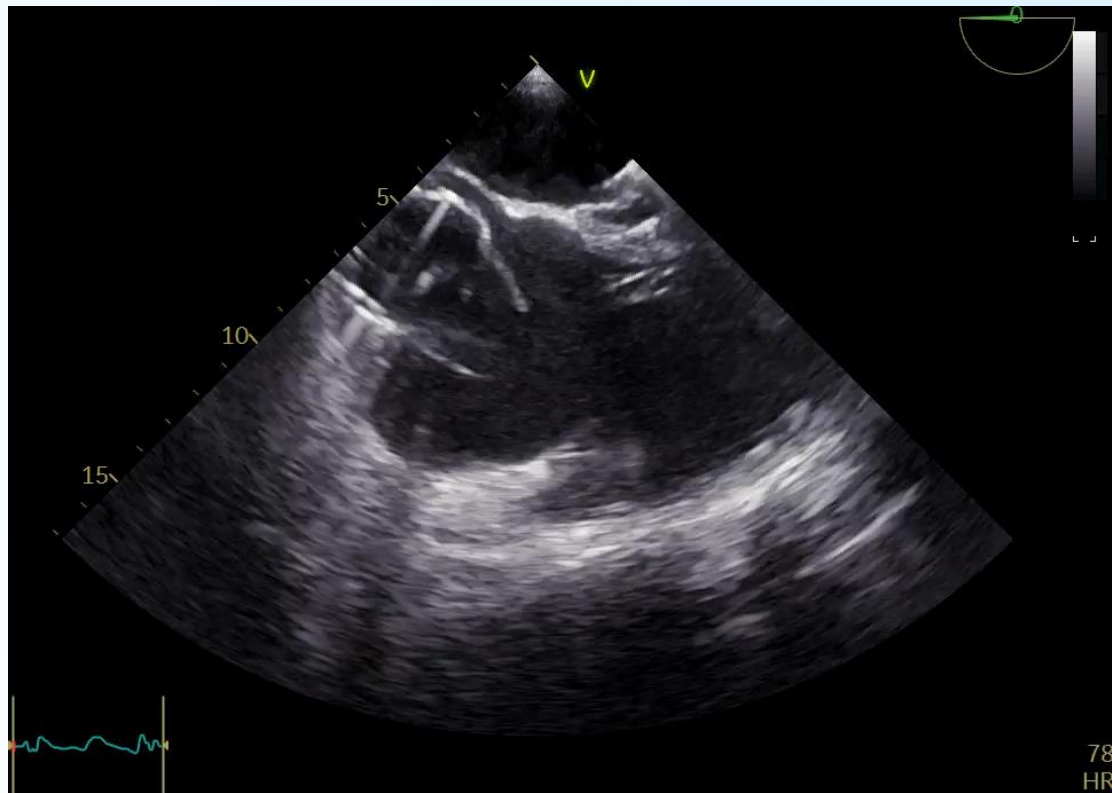
Anatomia non favorevole per triclip

Si propone impianto di Tricento

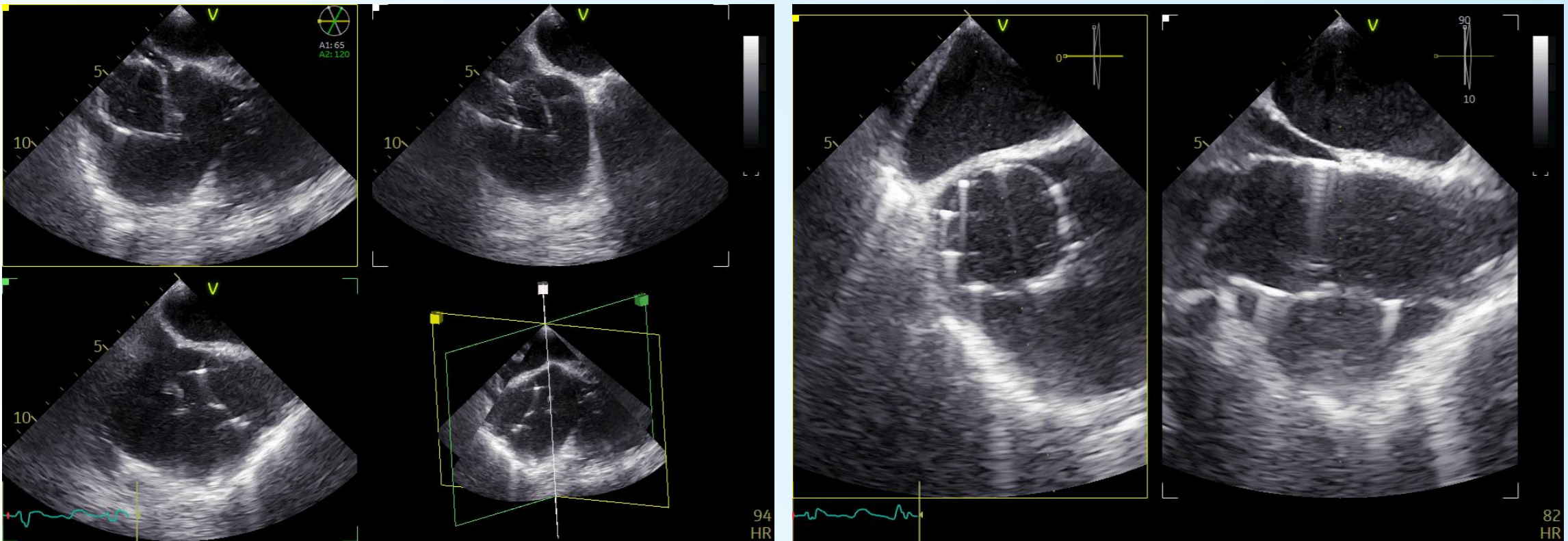
Caso clinico 2



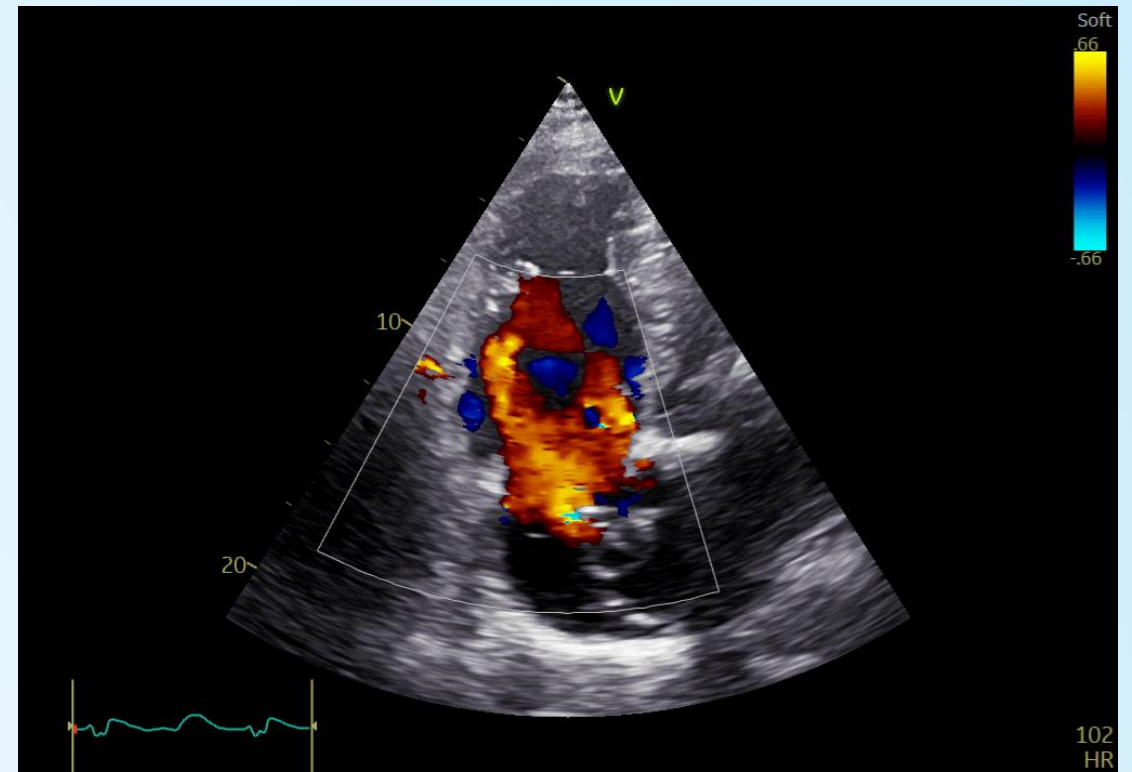
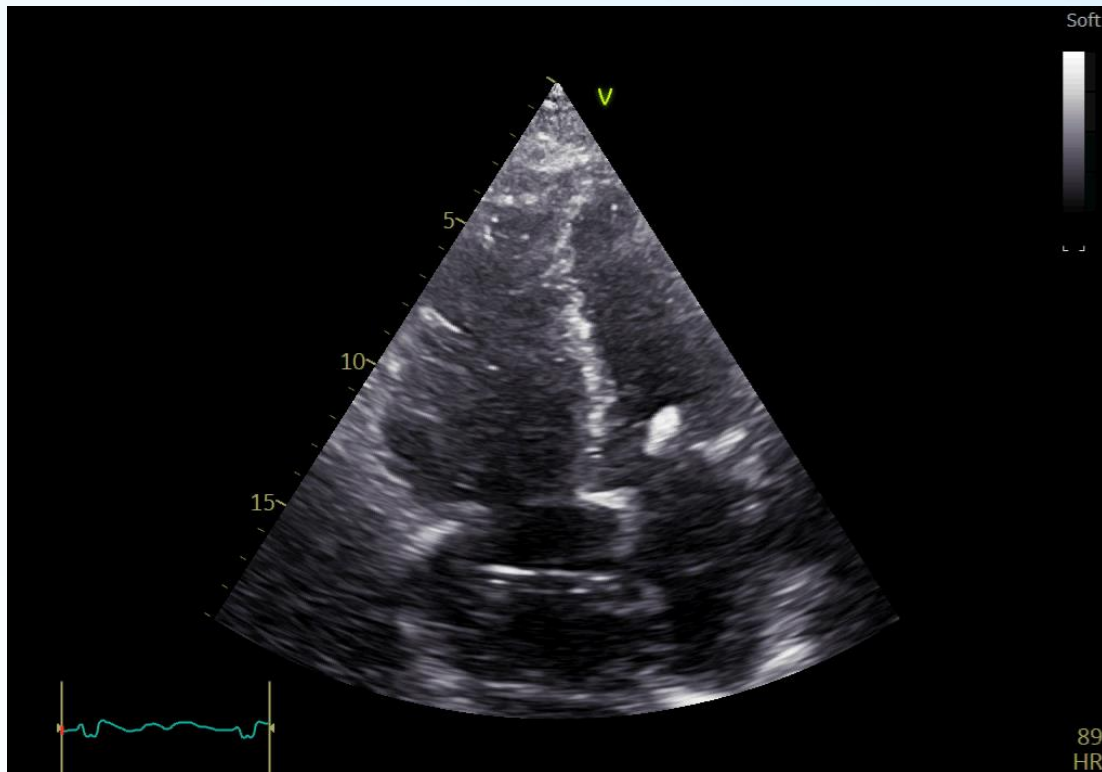
Caso clinico 2



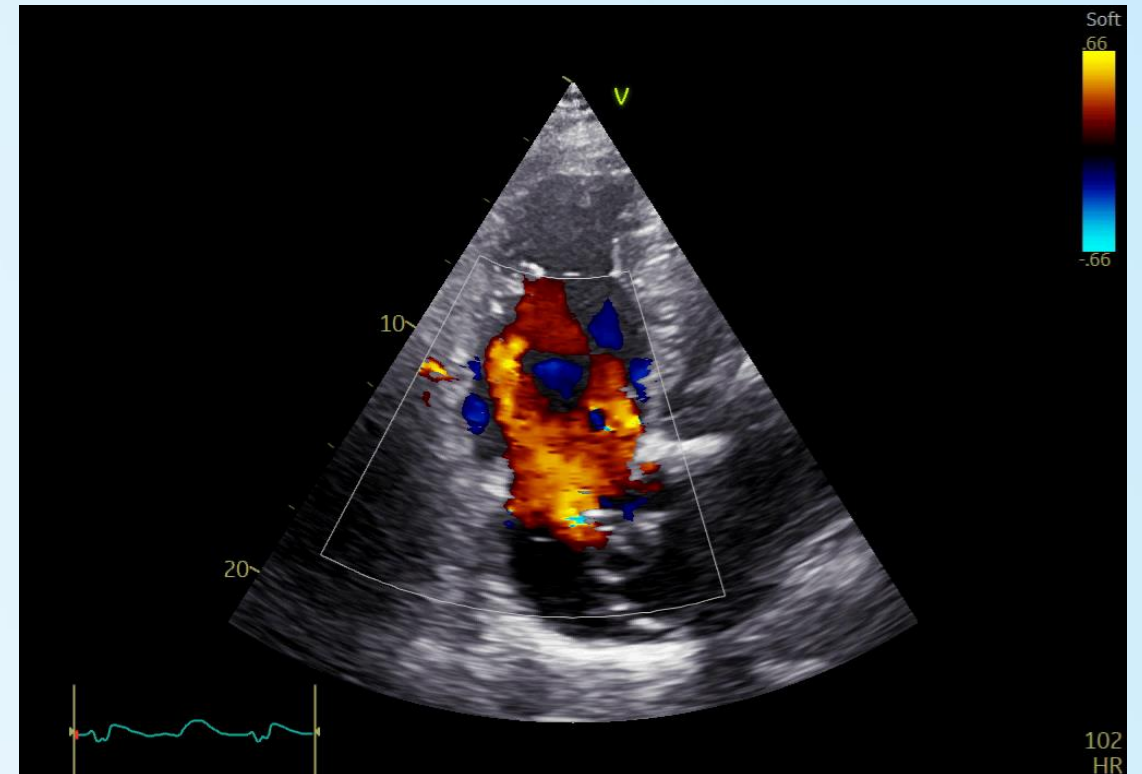
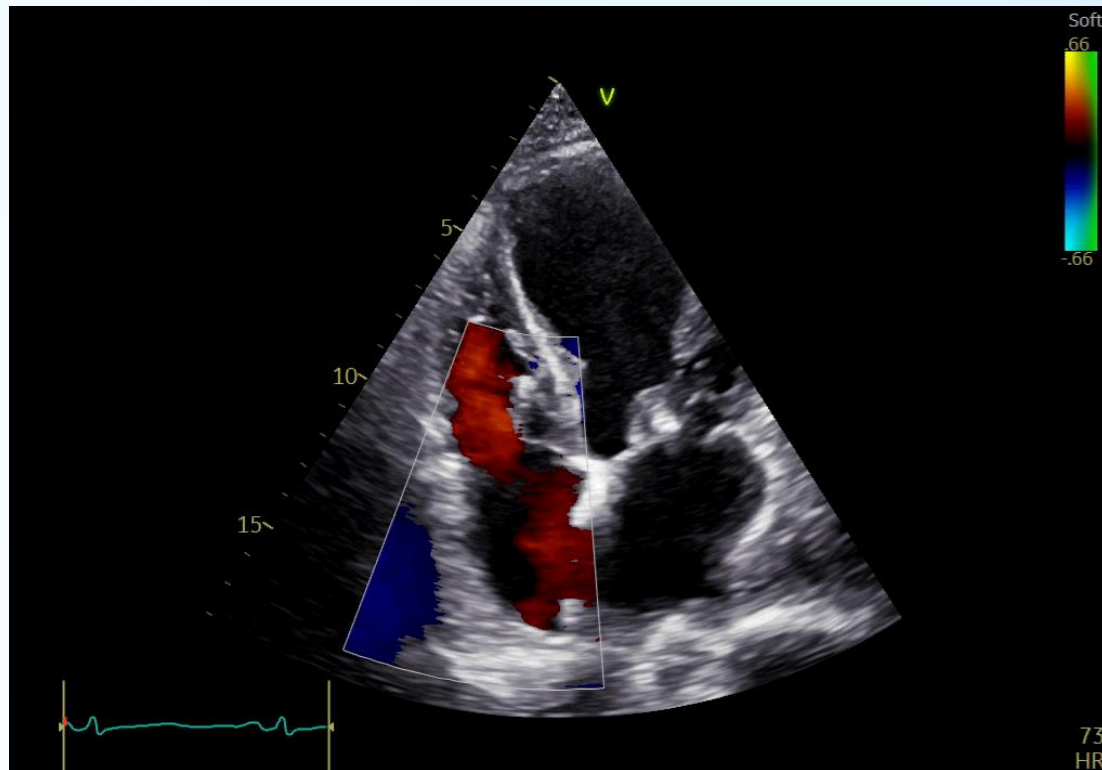
Caso clinico 2



Caso clinico 2



Triclip vs Tricento



TAKE HOME THE MESSAGE:

TIMING DELLA CORREZIONE DELL'INSUFFICIENZA TRICUSPIDALE E' FONDAMENTALE

CORREZIONE MEDIANTE TRICLIP MIGLIORA LA PROGnosi E LA SINTOMATOLOGIA DEI PAZIENTI

SE SI ARRIVA A TECNICHE ALTERNATIVE (TRICENTO) POTREBBE ESSERE TROPPO TARDI